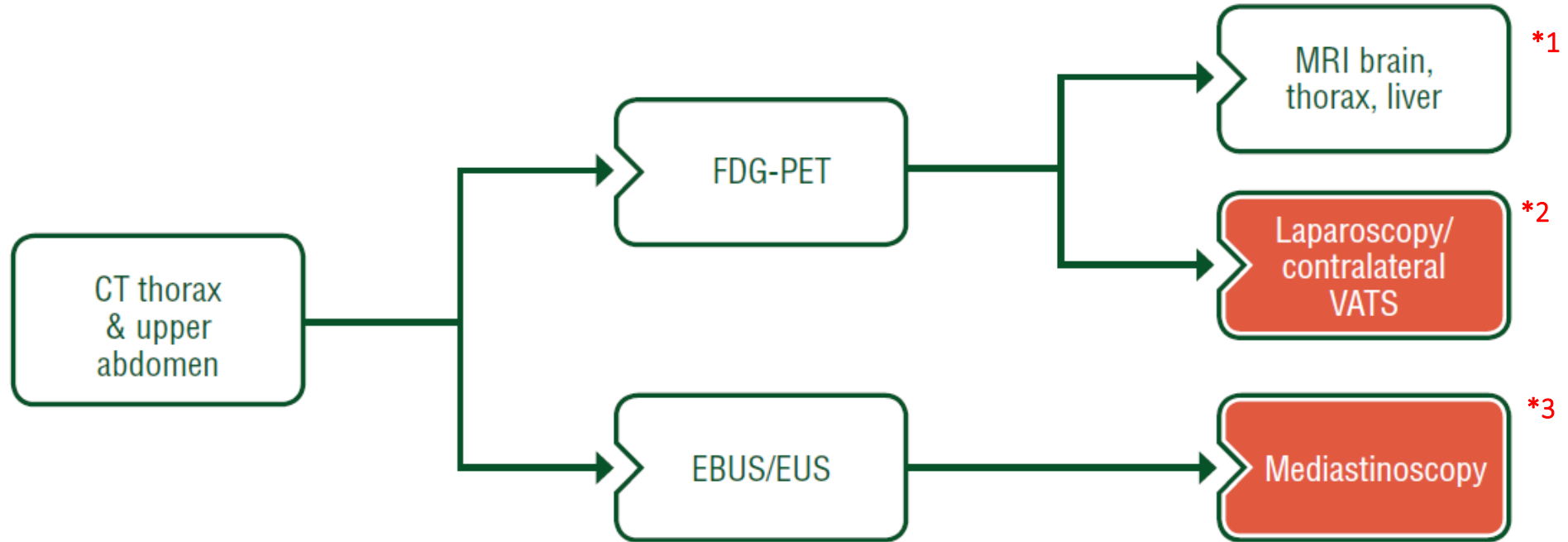


Basic staging in  
all patients

Staging in those suitable for  
multimodality treatment

Staging in those with borderline  
resectability prior to radical surgery  
(if suspicion of involvement)



**LLCG/VZN annotations**

1. *DWI (Diffusion-weighted Imaging) MRI Thorax with measurement of Apparent Diffusion Coefficients (ADC) can be helpful for defining operability in difficult cases.*
2. *Contralateral VATS only on (rare) indication.*
3. *Routine EBUS/EUS/Mediastinoscopy/Laparoscopy for all MPM patients, potentially eligible for surgical combined modality treatment. In case of cN2 MPM on PET/CT, pathologic sampling with EBUS/EUS may be preferred first.*